

# Frontal precentral oligodendroglial gross-total lesionectomy and control of partial motor seizures in a child

Abraham Ibarra-de la Torre<sup>1</sup>, Verónica Bautista-Piña<sup>2</sup>, Antonio Avilés-Aguilar<sup>1</sup>

## ABSTRACT

The oligodendrogliomas, are brain tumors with origin glial, grade II by WHO classification for cerebral tumors in humans, are more frequency in adults and few cases or rare in children; their common presentation and localization is with seizures and frontal lobe cortical and/or subcortical, respectively. A prognostic factor is the resection grade and the follow-up to long time and includes the oncologic. We presented one case in a child with a gross-total resection frontal-precentral oligodendrogloma and control of seizures.

**Key words:** oligodendrogloma, child, molecular genetics, computed tomography.

## Control de crisis convulsivas en un niño con resección de oligodendrogloma frontal

## RESUMEN

Los oligodendrogliomas, son tumores cerebrales de origen glial, grado II de la clasificación de la Organización Mundial de la Salud (OMS) para tumores cerebrales en humanos; son más frecuentes en adultos y pocos o raros en niños; su presentación y localización común es con crisis convulsivas y en lóbulo frontal cortical y/o subcortical, respectivamente. Un factor pronóstico es el grado de resección y seguimiento a largo plazo e incluye oncológico. Presentamos el caso de un caso pediátrico con resección amplia subtotal de oligodendrogloma frontal – precentral y control de crisis convulsivas.

**Palabras clave:** oligodendrogloma, niño, genética molecular, tomografía computada.

**T**he oligodendrogloma, a diffusely infiltrating tumor, origin from the normal glial cell of brain called oligodendrocytes, is a well-differentiated glioma and the majority arise in adults, is rare in children; corresponds histologically for the international classification of tumours published by the World Health Organization (WHO) grade II or grade III for anaplastic oligodendrogliomas; the *International Classification of Diseases for Oncology* (ICD-O) is a histology (morphology) code for oligodendrogloma is 9450/3<sup>1-4</sup>. The oligodendrogloma occur in the frontal lobe in 50-65%; especially in the cortex and white matter. The clinical features, symptoms and signs, the patients present with seizures, signs of increased intracranial pressure, as

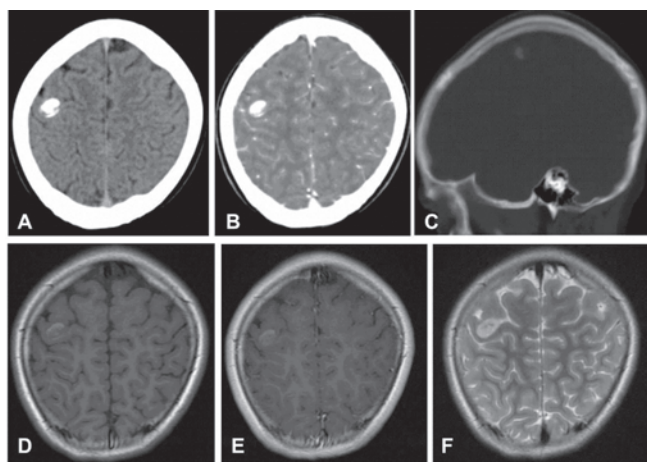
headache or focal neurological deficit, cognitive or mental changes<sup>1,5,6</sup>. We present a child of th 2nd decade of the life with partial motor seizures and oligodendroglial tumor in the frontal lobe-precentral that had a successful outcome after gross-total resection and brief review of the literature.

Recibido: 25 de julio 2014. Aceptado: 19 de agosto 2014.

<sup>1</sup>Departments of Neurosurgery, <sup>2</sup>Pathology of Hospital Central Sur de Alta Especialidad, PEMEX. Correspondence to Abraham Ibarra-de la Torre. Departments of Neurosurgery of Hospital Central Sur de Alta Especialidad, PEMEX, Av. Periférico Sur # 4091, Col. Fuentes del Pedregal 14140, Mexico, D. F. E-mail: abrahamibarra@hotmail.com

## Case report

An 11 year old age female that presented with left partial motor seizures (hand and foot) mean one or two times for day, one or two times to month eleven months pre-surgery; in the neurological examination without relevance. *Neuroimaging.* Computed tomography (CT), round lesion with hyperdensity, right frontal lobe-precentral and magnetic resonance imaging (MRI) this tumor calcified partially, measure 12.9x11.3x14.3 millimeter, anterior-posterior, superior-inferior and transversal, respectively.



**Figure 1.** Neuroimaging. Right intra-axial lobe frontal-precentral partially calcified lesion, computed tomography (A, simple; B, contrast and C, sagittal bone window) and magnetic resonance imaging (D, axial T1 weighted, E, Axial T1 weighted with contrast and F, axial T2 weighted), measure 12.9x11.3x14.3 millimeter, anterior-posterior, superior-inferior and transversal, respectively.

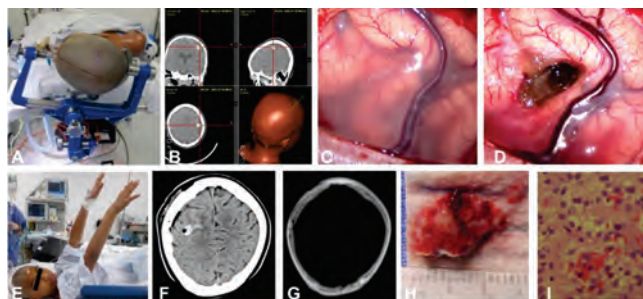
*Electroencephalography:* no paroxysmal discharges. *Surgery.* Gross-total resection of subcortical of the frontal lobe-precentral tumor well-defined greyish colour, using a neuronavigation system for orientation during surgery. *Pathology.* Oligodendroglioma; cells with round nuclei and perinuclear halos, *fried egg* appearance.

*Follow-up.* The initial follow-up, the patient had transient left hand paresis, without seizures at four months post-surgical; with oncologic evaluation for adjuvant therapy.

## DISCUSSION

The oligodendroglioma is a diffusely infiltrating tumor, corresponds histologically for the international classification of tumours published by the WHO grade II and rare in children<sup>1-4,6</sup>; same to knowledge in the Hospital Central Sur de Alta Especialidad. We presented an uncommon case report of a child with oligodendroglioma

and successful outcome post-surgical gross-total resection.



**Figure 2.** Imaging intraoperative. Planning using a neuronavigation system for orientation during surgery (A, B); Pre- (C) and post-resection (D) piecemeal for precentral 9.0 millimeter surcotomy. Immediate post-resection, clinical image (E) and control tomography computed simple (F) and bone window (G); too have magnetic resonance imaging post-surgical (not show). Pathology, macroscopic (H) and photomicroscope (I) tumor, cells with round nuclei and perinuclear halos (*fried egg* appearance).

The oligodendroglioma have clinical features, symptoms and signs, the patients present with seizures, signs of increased intracranial pressure, as headache or focal neurological deficit, cognitive or mental changes<sup>1,5,6</sup>. The oligodendroglioma occur in the frontal lobe in 50-65% of the patients, especially in the cortex and white matter; too patients have been reported with oligodendroglioma localized in posterior fossa, mesencephalon, basal ganglia, thalamus, brainstem, cervical medulla or spinal cord, as well as primary leptomeningeal oligodendroglioma or oligodendroglial gliomatosis cerebri<sup>1,4,7-12</sup>. The oligodendroglial tumours comprise two entities, pure oligodendrogliomas and mixed oligoastrocytomas, that comprise 5–20% of all glial tumours<sup>13</sup>; represent 3 to 5% of primary brain tumors<sup>14</sup>.

In the oligodendrogliomas have identification loss of heterozygosity (LOH) 1p/19q (1p: short arm of chromosome; and 19q: long arm of chromosome 19) was frequent in oligodendrogliomas in 69% (from 50% to 80%) and TP53 mutations are genetic hallmarks for these tumor<sup>15</sup>; this add to characterization of pathologic variables and their influence on prognosis<sup>16</sup>. constitutes an independent prognostic marker, with 1p or 19q loss being associated with improved outcome regardless of the specific therapeutic regimen. By WHO 2007 criteria, the diagnosis is based entirely on morphologic features, without consideration of molecular genetic characteristics, and is very subjective with high interobserver variability<sup>17</sup>.

The patients with brain tumor in childhood are at significant risk of tumor progression<sup>18</sup> and many these patients require prolonged oncological follow-up; and

advances in the clinical and molecular stratification for many types of childhood brain tumors have provided a foundation for risk-adapted treatment planning and improvements in outcome<sup>19</sup>.

For the oligodendrogliomas is known favorable prognostic factors include age younger than 40 years, low tumor grade, and extent of resection<sup>14</sup>; at present case, have favorable prognostic factors.

### CONCLUSION

The oligodendroglioma is a brain tumor with origin from oligodendrocytes, WHO grade II, is rare or unusual in children that their appropriate diagnosis and management as extent surgical and oncologic follow-up prolonged, improvement the attention in these patients with oligodendroglioma. At the present case, have similar characteristics as the literature.

### Acknowledgments

To Gloria Angélica Díaz Méndez, M. D, by his effort made in the preparation of these paper.

### REFERENCES

1. Reifenberger G, Kros JM, Louis DN, Collins VP. Oligodendroglioma. En: Louis DN, Ohgaki H, Wiestler OD, Cavenee WK. (editores), WHO Classification of Tumours of the Central Nervous System. International Agency for Research on Cancer, Lyon 2007: 54-9.
2. Louis DN, Ohgaki H, Wiestler OD, Cavenee WK, Burger P. C, Jouvett A, Scheithauer WB, Kleihues P. The 2007 WHO classification of tumours of the central nervous system. *Act Neuropathol* 2007; 114:97-109.
3. Rorke LB, Gilles FH, Davis RL, Becker LE. Revision of the World Health Organization Classification of Brain Tumors for Childhood Brain Tumors. *Cancer* 1985; 56:1869-86.
4. El Ouni F, Gaha M, Moulahi H, Daadoucha A, Krifa H, Tlili K. Infratentorial Oligodendroglioma in a Child: a case report and review of the literature. *Turkish Neurosurgery* 2012;22:461-4.
5. Lynam LM, Lyons MK, Drazkowski JF, Sirven JI, Noe KH, Zimmerman RS, Wilkens JA. Frequency of seizures in patients with newly diagnosed brain tumors: a retrospective review. *Clin Neurol Neurosur* 2007;109:634-8.
6. Shaw EG, Scheithauer BW, O'Fallon JR, Tazelaar HD, Davis DH. Oligodendrogliomas: the Mayo Clinic experience. *J Neurosurg* 1992;76:428-34.
7. Peters O, Gnekow AK, Rating D, Wolff JE. A. Impact of Location on Outcome in Children with Low-Grade Oligodendroglioma. *Pediatr Blood Cancer* 2004;43:250-6.
8. Lunder T, Due-Tønnessen BJ, Egge A, Scheie D, Stensvold E, Brandal P. Neurosurgical treatment of oligodendroglial tumors in children and adolescents: a single-institution series of 35 consecutive patients. *J Neurosurg Pediatrics* 2013;12:241-6.
9. Ellenbogen JR, Perez S, Parks C, Crooks D, Mallucci C. Cerebellopontine angle oligodendroglioma in a child; first case report. *Childs Nerv Syst* 2014; 30:185-7.
10. Mittelbronn M, Wolff M, Bültmann E, Thomas Nägele T, Capper D, Beck R, Meyermann R, Beschorner R. Disseminating anaplastic brainstem oligodendroglioma associated with allelic loss in the tumor suppressor candidate region D19S246 of chromosome 19 mimicking an inflammatory central nervous system disease in a 9-year-old boy. *Human Pathology* 2005; 36: 854-7.
11. Nam DH, Cho BK, Kim YM, Chi JE, Wang KC. Intramedullary anaplastic oligodendroglioma in a child. *Child's Nerv Syst* 1998;14:127-30.
12. Baysefer A, Düz B, Erdogan E, Deveci MS. Pediatric cerebellar cystic oligodendroglioma: case report and literature review. *Turkish J Pediatrics* 2004; 46: 95-7.
13. Jenkinson MD, Walker C, Brodbelt AR, Wilkins S, Husband D, Haylock B. Molecular genetics, imaging and treatment of oligodendroglial tumours. *Act Neurochir* 2010;152:1815-25.
14. Lebrun C, Fontaine D, Ramaioli A, Vandenbos F, Chanalet S, Lonjon M, et al. Long-term outcome of oligodendrogliomas. *Neurol* 2004; 62:1783-7.
15. Ohgaki H, Kleihues P. Population-based studies on incidence, survival rates, and genetic alterations in astrocytic and oligodendroglial gliomas. *J Neuropathol Exp Neurol* 2005; 64:479-89.
16. Burger PC. The "Ideal" Classification of Pediatric Central Nervous System Neoplasms. *Cancer* 1985; 56:1865-8.
17. Fuller GN, Ribalta T. Brain tumors: an overview of current histopathologic classifications. En: Winn H. R. (editor) Youmans Neurological Surgery, Philadelphia, 6th ed, Volume 2, 2011:1077-86.
18. Vinchon M, Baroncini M, Leblond P, Delestret I. Morbidity and tumor-related mortality among adult survivors of pediatric brain tumors: a review. *Childs Nerv Syst* 2011; 27:697-704.
19. Pollack IF. Multidisciplinary management of childhood brain tumors: a review of outcomes, recent advances, and challenges. *J Neurosurg Pediatrics* 2011; 8:135-48.

ARTÍCULO SIN CONFLICTO  
DE INTERÉS