

# Psychogenic non-epileptic seizures following COVID-19 vaccine: A report of two cases in Colombia

Villalobos-Comas Julio Cesar<sup>1</sup> | Castillo-Támara Edgard Eliud<sup>2</sup> | Montaña-Lozada Juan Manuel<sup>3</sup> | Cardona-Moica Sandra Marcela<sup>4\*</sup>

1. Neurologist, Universidad Nacional Autónoma de México. Liga Cordoba contra la Epilepsia, Córdoba, Colombia.
2. Neurologist, Universidad de Buenos Aires, Buenos Aires, Argentina. Director of Neurology program, Universidad del Sinú "Elías Bechara Zainum", Cartagena Colombia.
3. Neurologist, Universidad del Sinú "Elías Bechara Zainum" Cartagena, Colombia
4. Resident of Neurology, Universidad del Sinú "Elías Bechara Zainum" Cartagena, Colombia.

## Correspondence

Sandra Marcela Cardona Moica  
Calle 95 #47-25 Edificio Litanny, Barranquilla Colombia

✉ [mcardonam@ut.edu.co](mailto:mcardonam@ut.edu.co)

## Abstract

**Introduction:** The novel coronavirus SARS-CoV-2 has caused the death of more than 5 million of people worldwide. Vaccination is the best strategy for controlling the pandemic with an estimated of more that 4 million of people completely vaccinated. The reported adverse events secondary to vaccines against SARS-CoV-2 are mainly mild and moderate, however, there are raising concerns about more severe and long-term outcomes, as well as neurological complications due to the vaccine.

**Methods:** We present two cases of psychogenic non epileptiform seizures (PNES) in Colombian female patients following vaccination against COVID-19. There is no evidence of similar adverse reactions reported on the literature.

**Discussion and conclusion:** We report these events in order to help clinicians in recognizing early and properly all the possible neurological manifestations related to COVID vaccine application, which is aimed to control the current pandemic and its devastating worldwide consequences in terms of health and social issues.

**Keywords:** COVID-19, pandemic, post-vaccine events, psychogenic non epileptiform seizures, SARS-CoV-2, vaccination.

## Background

The coronavirus SARS-CoV-2 is the pathogen responsible of the COVID-19 pandemic, which has caused the death of more than 5 million of people worldwide since its beginning. SARS-CoV-2 infection causes an acute severe respiratory syndrome and multi-organ involvement, including cardiovascular, musculoskeletal, gastrointestinal, and neurological complications.<sup>1</sup> This scenario poses a challenge for public health systems, focusing the entire scientific community on the development of an urgent strategy to control infection spreading.

At present, vaccination is the best method for controlling the pandemic, with an estimated of more than 4 billion people fully vaccinated. The increment of vaccination strategies has reduced the risk of SARS-CoV-2 infection in 90% and, as reported in the International League Against Epilepsy (ILAE) statement, risk of infection far outweighs the possible risks of being vaccinated.<sup>2</sup>

Although adverse events following administration of COVID-19 vaccines are mainly mild and moderate,<sup>2-3-4</sup> there are raising concerns about more severe and long-term outcomes. Neurological complications are rare but cases of stroke, cranial neuropathies, peripheral neuropathies, encephalomyelitis and transverse myelitis<sup>6</sup> were reported, revealing the importance of further research on neurological outcomes post-vaccination.

Currently, there is no evidence linking seizures or epilepsy and COVID-19 vaccination.<sup>5-6</sup> However, a case of new-onset refractory status epilepticus following the ChAdOx1 nCoV-19 vaccine (AstraZeneca)<sup>7-8</sup> was reported, in addition to the occurrence of functional neurological disorders (FND) after receiving the first dose of the vaccine.<sup>9</sup> The purpose of this report is to present two cases of Colombian female patients who presented paroxysmic non epileptiform seizures (PNES) following administration of the first dose of the COVID-19 vaccine.



©2022 © National Institute of Neurology and Neurosurgery Manuel Velasco Suárez. Open access articles under the terms of the Creative Commons Attribution-Non-Commercial 4.0 International (CC BY-NC 4.0) license, which permits use, distribution and reproduction in any medium, provided the original work is properly cited. No commercial re-use is allowed."

### Patient 1

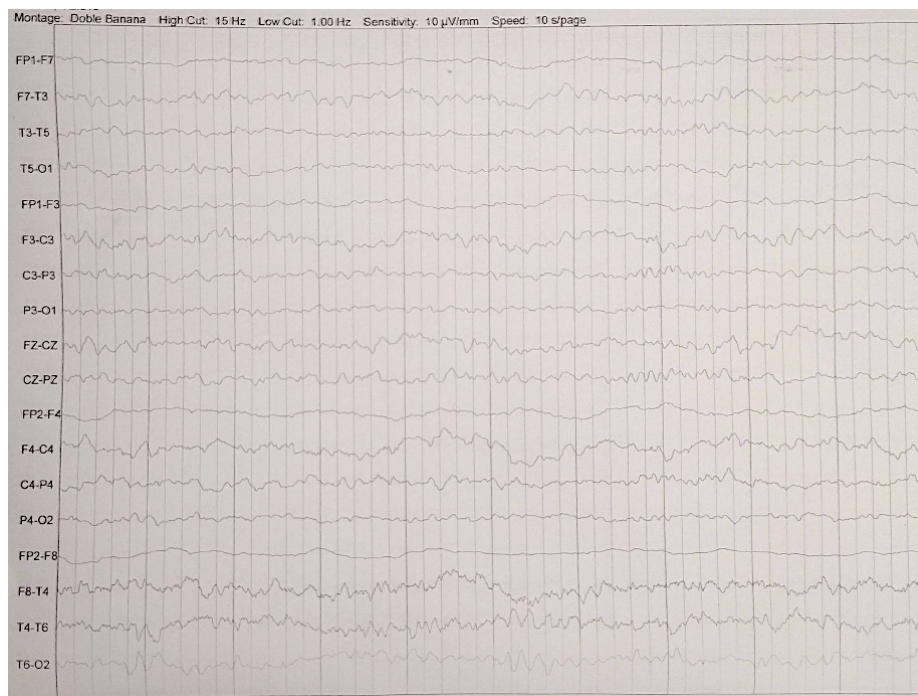
A 33-year-old female (first-line healthcare worker), with no significant medical records, initiates with upper limbs contractures and tonic postures approximately 14 minutes after receiving the BNT162b2 COVID-19 mRNA vaccine (Pfizer-BioNTech), resulting in ten episodes of unknown lasting. The patient was administered with benzodiazepines, was transferred to a higher-level institution and admitted to the intensive care unit (ICU).

Upon admission to the ICU, she referred mild global headache and drowsiness, associated with sedative therapy. The patient had symmetrical strength and sensitivity, preserved deep tendon reflexes, and normal orientation in space and time.

Laboratory tests initially showed leukocytosis and neutrophilia with a decreasing tendency, and no signs of systemic infection, toxicity or inflammatory response. Non-contrast brain computed tomography (CT) and simple-contrast brain magnetic resonance images (MRI) reported normal.

Serum prolactin was normal, cerebrospinal fluid (CSF) cytochemistry was unremarkable and cultures were negative. Liver and kidney function as well as clotting times were normal. T-T echocardiogram, immunological profile, serum electrolytes, blood gases and blood glucose levels were normal.

At the ICU, the patient's crises were observed by her relatives. These episodes were characterized by the presence of closed eyes, denial head movement, salivation and spitting, shoulder elevation, upper limb extension, pelvic movements of flexion-extension that lasted more than 2 minutes, without tongue biting or sphincter relaxation. The 48-hour video-electroencephalogram (VEG) reported no epileptiform activity (**Figure 1**). The patient improved progressively and remained free of paroxysmal events. She did not receive any anticonvulsant drugs. The patient presented an episode of auto aggression (mild cranial trauma without major complications), and psychiatric evaluation detected anxiety and depression disorder. She was diagnosed with psychogenic nonepileptic seizures and was discharged with mental health and internal medicine follow-up.



**Figure 1.** Patient 1: (VEG) for 48 hours, 10/20 international system, 32-channel digital equipment brand XLTEK model TREX. It is concluded: Background rhythm of alpha – beta base during wakefulness, adequate sleep pattern, no evidence of sharp waves, spikes or poly-spikes, no inter-ictal activity, within normal parameters.

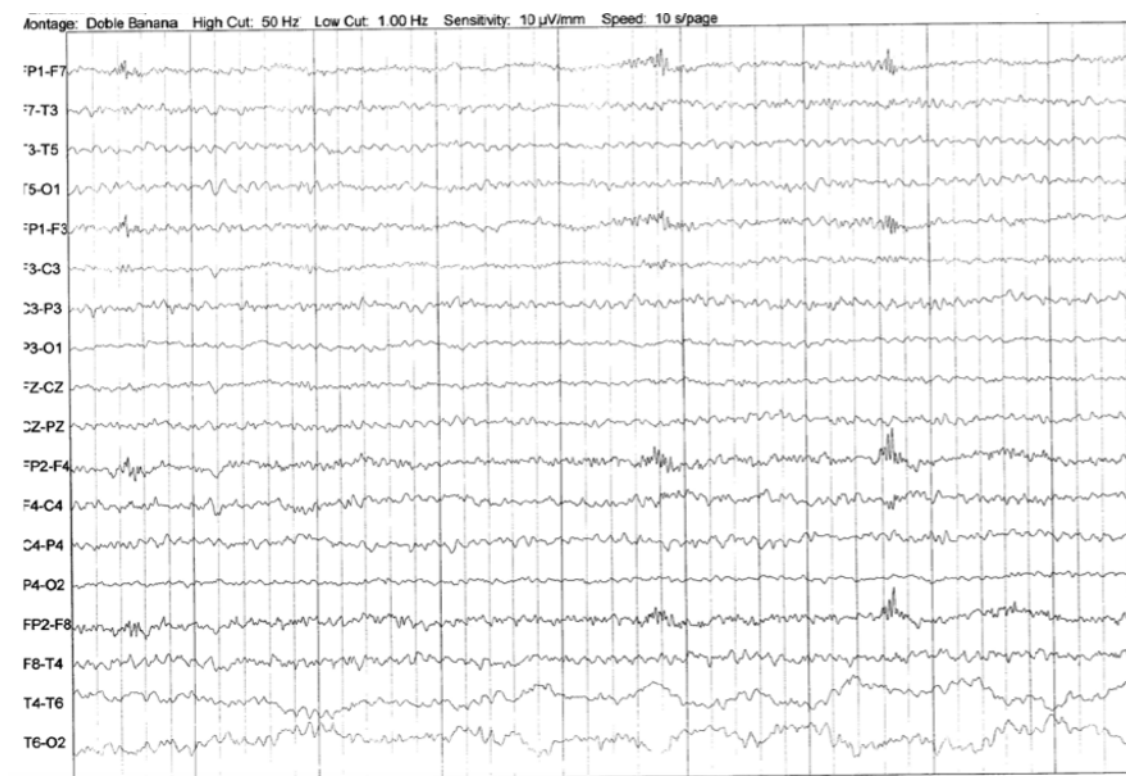
### Patient 2

A 26-year-old female nurse, single mother householder, with a history of abuse, adolescent pregnancy, and no-comorbidities. Ten minutes after receiving the first dose of the whole inactivated virus COVID-19 vaccine Sinovac, the patient presented foot dysesthesias and paresthesias, and altered perception of body heat. Four hours later, she was admitted due to an exacerbation of initial symptoms and then presented a total of 12 episodes characterized by eyes tightly closed, opened oral cavity without tongue lesions, denial cephalic movements, extension of upper extremities, and pelvic flexion-extension movements with great amplitude.

She was transferred to ICU for neurological monitoring. The patient had normal vital signs, symmetrical strength and sensitivity, preserved deep tendon reflexes, and normal

orientation in space and time. She was managed with intravenous rehydration, closely monitored and remained free of paroxysmal events.

Serum complementary studies performed: complete blood count, acute phase reactants, VDRL, HIV, serum prolactin, ferritin, PCR test for SARS CoV-2, D dimer, CPKMB, thyroid profile, LDH, liver and kidney function, serum electrolytes and conventional toxic test; all reported within normal ranges. Additionally, a 24-hour (VEG) was reported without epileptiform activity (**Figure 2**). CSF studies and cerebral images (CT and MRI) reported normal. She presented progressive improvement with no new events, and did not receive anticonvulsant treatment. The patient was discharged with comprehensive and interdisciplinary mental health and internal medicine follow-up.



**Figure 2.** Patient 2: (VEG) 24 hours, 10/20 international system, 32-channel digital equipment brand XLTEK model TREX. It concludes: Background rhythm of alpha – beta base during wakefulness, adequate sleep pattern. During “paroxysm” episode, it showed abundant rapid activity with morphology of muscular contraction devices, without sharp waves, spikes or polyspots that could suggest ictal or inter ictal activity, within normal parameters.

## Discussion

The rapid development and administration of the vaccine against SARS CoV-2 has proved to be the best strategy to control the growing pandemic caused by COVID-19. The general population (60-80%) is convinced that the benefits of vaccination outweigh its risks<sup>9</sup> and, in Colombia, there is an estimate of more than 30 millions of people with a complete vaccination scheme.<sup>10</sup> However, there is still a remaining population who haven't received any vaccinations because of their beliefs about possible adverse effects and misinformation.

In 2021, the World Health Organization published its recommendations for the use of existing COVID-19 vaccines, mainly reporting mild adverse effects during clinical trials, such as injection site pain, fatigue, headache, muscle pain, chills, fever, nausea, rash and pain in extremities. In post-authorization experience studies there has been reports of severe allergic reactions, including anaphylaxis, urticaria and syncope.<sup>11</sup> Regarding VAC31518 COVID-19 vaccine (Janssen) and Sinovac, the "Summary of instructions for COVID-19 vaccination providers" reported the development of seizures in the post-licensure safety monitoring of the components.<sup>12</sup> In these cases, although an immune basis is suspected, the causes are not entirely understood and further studies are required.

The American Academy of Neurology reported in 2021 the most common neurological conditions included in the Centers for Disease Control (CDC) Vaccine Adverse Event Reporting System (VAERS), namely, rare cases of tremor, diplopia, tinnitus, dysphonia and reactivation of herpes zoster. There were also cases of stroke, Guillain Barré syndrome, facial palsy, transverse myelitis and acute disseminated encephalomyelitis.<sup>6</sup> Nonetheless, there is a lack of information regarding the development of Functional Neurologic Disorders (FND) after the application of the vaccine, which is the case of the patients reported in the present document.

FNDs refer to disabling conditions in which people may experience neurological symptoms arising from brain networks dysfunction in absence of damage or structural disease, and with or without psychosocial stressors.<sup>13</sup> FNDs includes psychogenic non-epileptic seizures, which have specific characteristics that may help in seizure differential diagnoses. PNES are also a manifestation of immunization stress-related response (ISRR) clusters, as was reported in a study of PNES following HPV vaccination in Rio Branco, Brazil. According to this investigation, in a suspected outbreak of

an ISRR cluster following human papilloma virus vaccination (HPV), ten patients were diagnosed with PNES after prolonged intensive video- electroencephalography monitoring and extensive medical studies.

In here we present the cases of two patients whose symptoms started after the application of Sinovac and Pfizer vaccines, and were characterized by sudden onset and overt inconsistency, as typically observed in patients with PNES. Both showed acute paroxysms of hyperkinetic movements, subjective and objective manifestations that resembled epileptic seizures with absence of clear neurological semiology (determined after neurology consultation), as well as a video-electroencephalographic record with absence of seizures and epileptiform discharges, and brain images that didn't suggest structural lesions or systemic pathology.<sup>12</sup>

According to evidence, PNES are more common in females (71%).<sup>13</sup> Its diagnosis is complex even for experts and must be clearly distinguished from epileptic seizures. A complete anamnesis and a clearly described semiology of the event, along with trust and empathy towards the patient and their relatives, and complementary imaging and neurophysiological studies are the basis for a proper identification. In the present report, the correct diagnosis prevented the administration of anticonvulsant drugs to the patients, avoiding the adverse effects of this medication, as they could increase comorbidities and even cause deep sedation and death.

An alternative diagnosis is conversion disorder, since PNES can be a clinical manifestation of it, however, there was not a causative psychological stressor in close temporal relation to the onset of the FND symptoms in the patients. Factitious and malingering disorders were less probable, considering that a behavior governed by a cost-benefit analysis was not detected during psychiatric intervention.

We consider the presentation of these cases of great medical interest because they involved healthcare workers in the time of the first vaccination phase in Colombia; the presence of such circumstances in the vaccination programs has had a great impact in public reception. As an example, the vaccination against human papilloma (HPV) in 2014 was previously affected by the development of FND in a town near Carmen de Bolívar, Colombia, which led to a low vaccination target rate of less than 4%.<sup>13</sup> There have also been reports of FND and PNES in association with other vaccines, fortunately, these episodes were related with complex social factors that were triggered by the immunization process, and not by the vaccine itself.<sup>16</sup>

Taking into account that vaccines against COVID-19 are still in phase IV trials, reporting its possible adverse effects is an obligation for healthcare providers, as well as optimizing their data base regarding compounds safety and security, and recognizing possible post-vaccination severe complications.

## Conclusions

Vaccination programs in Colombia are progressing adequately to mitigate the impact of the COVID-19 infection, remaining the best strategy in the fight against such a terrible disease. However, there are still some concerns about short- and long-term adverse events related to the vaccines.

This report demonstrates the association between COVID-19 vaccines and the development of PNES in two patients; this complication has been previously reported regarding other immune compounds, affecting population confidence in vaccination programs. Since no biological association has been found for FND and vaccines, this report has utility for encouraging health providers to discuss the best approach for patients with immunization stress-related response (ISRR), in order to guarantee a better understanding of the condition, and to also ensure vaccination compliance.

## Bibliography

- Huang C, Wang Y, Li X, Ren L, Zhao J, Hu Y, et al. Clinical features of patients infected with 2019 novel coronavirus in Wuhan, China. *Lancet*. 2020; 395(10223):497-506.
- International League Against Epilepsy. COVID-19 vaccines and people with epilepsy. Flower Mound: International League Against Epilepsy. 2022 <https://www.ilae.org/patient-care/covid-19-and-epilepsy/covid-19-vaccines-and-people-with-epilepsy#English>
- Food and Drug Administration. Fact sheet for healthcare providers administering vaccine (vaccination providers). Emergency use authorization (EUA) of the Moderna COVID-19 vaccine to prevent coronavirus disease 2019 (COVID-19). Maryland: FDA; 2022. <https://www.fda.gov/media/144637/download>
- Food and Drug Administration. Fact sheet for healthcare providers administering vaccine (vaccination providers). Emergency use authorization (EUA) of the Pfizer-Biontech COVID-19 vaccine to prevent coronavirus disease 2019 (COVID-19). Healthcare Providers for 12 years of age and older. Maryland: FDA; 2022. <https://www.fda.gov/media/153713/download>
- Fact sheet for healthcare providers administering vaccine (vaccination providers). Emergency use authorization (EUA) of the Janssen COVID-19 vaccine to prevent coronavirus disease 2019 (COVID-19). Warning: thrombosis with thrombocytopenia syndrome. Maryland: FDA; 2022. <https://www.fda.gov/media/146304/download>
- Lin K, Huang H, Fang S, Zheng G, Fu K, Liu N, et al. Should patients with epilepsy be vaccinated against coronavirus disease 2019? A systematic review and meta-analysis. *Epilepsy Behav*. 2022;134:108822.
- Aladdin Y, Shirah B. New-onset refractory status epilepticus following the ChAdOx1 nCoV-19 vaccine. *J Neuroimmunol*. 2021; 357:577629.
- Jackson LA, Anderson EJ, Roupheal NG, Roberts PC, Makhene M, Coler RN, et al. An mRNA Vaccine against SARS-CoV-2 — Preliminary Report. *N Engl J Med*. 2022; NEJMoa2022483.
- Goss AL, Samudralwar RD, Das RR, Nath A. ANA Investigates: Neurological Complications of COVID-19 Vaccines. *Ann Neurol*. 2021; 89(5):856-7.
- Ghosh R, Dubey S, Roy D, Mandal A, Naga D, Benito-León J. Focal onset non-motor seizure following COVID-19 vaccination: A mere coincidence? *Diabetes Metab Syndr Clin Res Rev*. 2021; 15(3):1023-4.
- Fasano A, Daniele A. Functional disorders after COVID-19 vaccine fuel vaccination hesitancy. *J Neurol Neurosurg Psychiatry*. 2022; 93(3):339-40.
- Ministerio de Salud y Protección Social. Vacunación contra COVID-19 [Internet]. Bogotá: Ministerio de Salud y Protección Social; 2022 [cited 2022 Mar 7]. Available from: <https://www.minsalud.gov.co/salud/publica/Vacunacion/Paginas/Vacunacion-covid-19.aspx>
- World Health Organization. Immunization, vaccines and biologicals [Internet]. Geneva: World Health Organization; 2022 [cited 2022 Mar 7]. Available from: <https://www.who.int/teams/immunization-vaccines-and-biologicals>
- World Health Organization. Background document on the inactivated vaccine Sinovac-CoronaVac against COVID-19 [Internet]. Geneva: WHO; 2021 [cited 2022 Mar 7]. Available from: [https://www.who.int/publications-detail-redirect/WHO-2019-nCoV-vaccines-SAGE\\_recommendation-Sinovac-CoronaVac-background-2021.1](https://www.who.int/publications-detail-redirect/WHO-2019-nCoV-vaccines-SAGE_recommendation-Sinovac-CoronaVac-background-2021.1)
- Espay AJ, Aybek S, Carson A, Edwards MJ, Goldstein LH, Hallett M, et al. Current concepts in diagnosis and treatment of functional neurological disorders. *JAMA Neurol*. 2018; 75(9):1132.
- Marchetti RL, Gallucci-Neto J, Kurcgant D, Proença ICGF, Valiengo L da CL, Fiore LA, et al. Immunization stress-related responses presenting as psychogenic non-epileptic seizures following HPV vaccination in Rio Branco, Brazil. *Vaccine*. 2020; 38(43):6714-20.
- Chen DK, Sharma E, LaFrance WC. Psychogenic non-epileptic seizures. *Curr Neurol Neurosci Rep*. 2017; 17(9):71.
- Reuber M, Jamnadas-Khoda J, Broadhurst M, Grunewald R, Howell S, Koeppe M, et al. Psychogenic nonepileptic seizure manifestations reported by patients and witnesses. *Epilepsia*. 2011; 52(11):2028-35.
- Bass C, Halligan P. Factitious disorders and malingering in relation to functional neurologic disorders. *Handb Clin Neurol*. 2016; 139:509-20. doi:10.1016/B978-0-12-801772-2.00042-4

Article without conflict of interest

© Archivos de Neurociencias