

Weber syndrome due to penetrating wound in midbrain

Víctor Hugo Escobar de la Garma¹, Ricardo Ramírez Aguilar¹, Omar Antonio Pérez Morales¹, Arturo Ayala Arcipreste², Felipe Padilla Vázquez¹, Rafael Mendizábal Guerra³

ABSTRACT

Weber syndrome usually presents due to ischaemic or aneurysmal rupture events; to our knowledge, its presentation after a penetrating brain injury has never been reported. Clinical presentation. We report the case of a 52-year male that was assaulted receiving a penetrating trauma in left malar region with brief lost of consciousness. He presented in emergency room with Glasgow coma scale of 9 points, global aphasia, left ptosis, external deviation and midriatic-fixed pupil of the left eye, and right hemiplegia. A CT scan was performed on admission, revealing an irregular linear hematoma from the silvian fissure through temporal parenchyma traversing left cerebral peduncle and affecting midbrain left tegmentum. In the next two weeks, the patient recovered muscle power in right arm and leg with subsequent hospital discharge. *Conclusion:* penetrating brain injuries affecting the brainstem are rare conditions with high mortality, survival with good prognosis is extremely rare. This is the first case of penetrating brain injury with associated Weber syndrome and survival with partial recovery.

Key words: mesencephalon, midbrain, penetrating trauma, Weber syndrome.

Síndrome de Weber secundario a trauma penetrante en mesencéfalo

RESUMEN

El síndrome de Weber; por lo general, se presenta secundario a eventos isquémicos o por ruptura aneurismática; hasta donde sabemos, su presencia debido a una lesión penetrante por arma blanca no ha sido reportada hasta la fecha. *Reporte de caso:* paciente masculino de 52 años que fue asaltado recibiendo un trauma penetrante en la región malar izquierda, con pérdida del estado de alerta transitoriamente. Fue atendido en el servicio de urgencias con Glasgow de 9 puntos, afasia global, ptosis izquierda, desviación lateral y midriásis fija del ojo izquierdo, además de hemiplejía derecha. Se realizó tomografía computada de cráneo a su ingreso reveló un hematoma irregular, lineal desde la fisura silviana a través del parénquima temporal y pedúnculo cerebral ipsilateral que afecta que el *tegmentum* mesencefálico izquierdo. En las siguientes semanas, el paciente recobró fuerza muscular en el brazo derecho y la pierna con subsecuente alta de este servicio. *Conclusión:* las lesiones penetrantes en el tallo cerebral son condiciones raras con alta mortalidad, la sobrevida con buen pronóstico es un evento raro. Este es el primer caso de trauma penetrante en mesencéfalo asociado a síndrome de Weber y sobrevida con recuperación parcial.

Palabras clave: mesencéfalo, trauma penetrante, región malar, síndrome de Weber.

Brainstem penetrating injuries are usually fatal lesions, few cases regarding survival to these injuries have been reported in the literature. The incidence of penetrating cranial injuries is rising, with a concomitant high morbidity and mortality. The prognosis of these depends in the type of weapon or item that caused the injury, the energy of impact, the localization

Recibido: 4 septiembre 2013. Aceptado: 27 septiembre 2013.

¹Residente Neurocirugía, ²Médico adscrito al Servicio de Neurocirugía, ³Jefe de Servicio de Neurocirugía, Hospital Juárez de México. Correspondencia: Víctor Hugo Escobar de la Garma. Neurocirugía, Hospital Juárez de México. Av. Instituto Politécnico Nacional 5133. Col. Magdalena de las Salinas. 07760 México, D. F. E-mail: tataboxboy@yahoo.com

and the intracranial trajectory. Wounds caused by knives have low velocity and small impact surface.

Medical literature describe alternate syndromes in which there is ipsilateral cranial nerve injury and contralateral long motor and/or sensitive tract lesion. Weber syndrome was described for the first time in 1838 by August Nikolaus Gendrin, but Joseph Grasset was the first who named it as we know it nowadays in honor to Sir Herman David Weber who published a case with ophtalmoplegia and contralateral hemiplegia in 1863⁵. This syndrome includes lesion of the nucleus of the third cranial nerve and fibers of the piramidal tract that cross the mesencephalon and present ptosis, midriasis, ophtalmoplegia, hemiparesis or hemiplegia. It is principally associated to lesions with mass effect or vascular abnormalities due to injury of perforating paramedian branches of posterior cerebral artery.

The majority of these kind of lesions are fatal, the cases reported in medical literature are predominantly with neurologic devastating secuelae.

We report a rare case and the first in literature of a lesion traversing the left cerebral peduncle with a knife and associated-Weber syndrome with survival and good prognosis.

Case presentation

A 52-year male with a history of 5-year hypertension treated with captopril was admitted in our hospital for being involved in an aggressive physical assault receiving a penetrating trauma in the left malar region with a knife. He lost briefly consciousness and posteriorly he presented with somnolence. There was no report of remotion of any penetrating object from the patient at the site of the event or at the emergency room. At physical examination he presented with a linear left malar wound already sutured at time of presentation, multiple facial echimosses and supraciliar lacerations. His vital signs were stable. Neurologic examination revealed Glasgow coma scale of 9 (O2V3M4), somnolence with intermitent episodes of motor agitation, motor aphasia, left ptosis, external deviation of left eye with absence of ipsilateral ocular movement and left fixed midriatic pupil. The movement of right eye was intact with responsive pupil. We found right hemiplegia, crural and brachial hyperreflexia and present right Babinski sign with ipsilateral spaticity.

On admission, a simple-computed tomography scan was performed that revealed a small single linear left-temporal squamous bone fracture and a linear irregular hematoma extending from the silvian fissure through the brain parenchyma to the left perimesencephalic cisterns and the left cerebral peduncle. There was a tiny

hyperdense lesion in midbrain that involved the left cerebral peduncle and the mesencephalo-diencephalic junction (figure 1, 2).

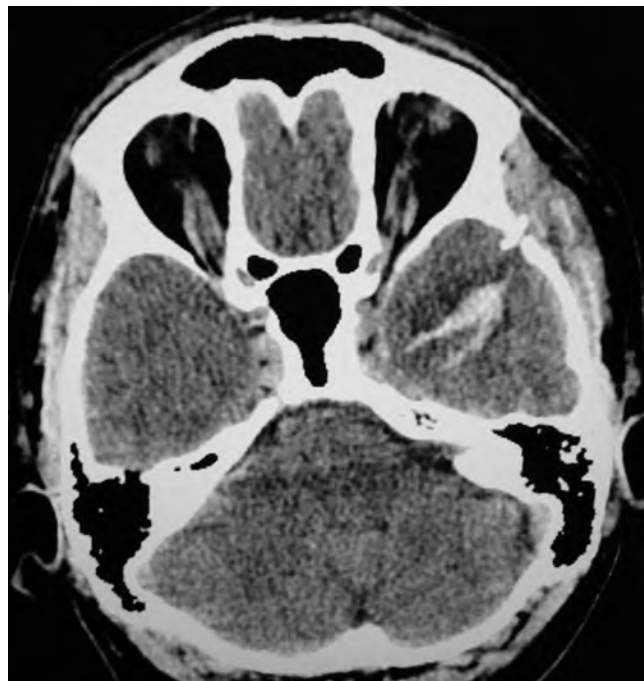

Figure 1. Non-contrasted cranial CT scan showing left squamous bone temporal fracture and hyperdense linear lesion traversing left temporal lobe parenchyma.

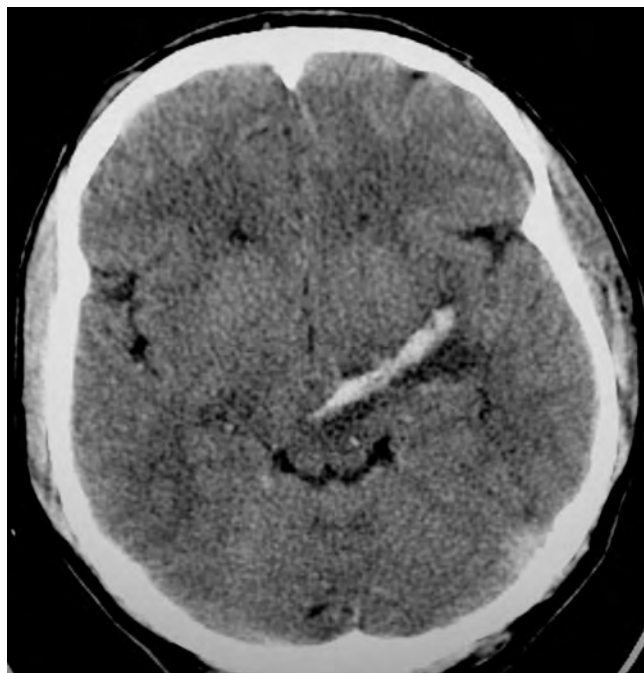


Figure 2. Non-contrasted cranial CT scan showing hyperdense trajectory of penetrating weapon through temporal parenchyma to midbrain affecting left cerebral peduncle.

A neurosurgical intervention was not realized because the hematoma never caused mass effect over brainstem and the patient did not exhibit signs of intracranial hypertension. Over the next 5 days the patient showed improvement in his consciousness and the motor deficit. Gadolinium-contrasted Magnetic Resonance Imaging showed a linear well-defined hypointense trajectory in left temporal parenchyma in axial T1/T2-weighted images respectively, and a well

defined lesion in left cerebral peduncle and tegmentum sparing the mesencephalic tectum (figure 3). MR angiography revealed no structural damage to any vessel, the left middle and posterior cerebral arteries were intact (figure 4).

After two weeks of hospital admission, the patient was discharged with clinical improvement, with motor aphasia and right hemiparesis with muscle power 2/5. The signs of left third cranial nerve lesion observed persisted until now.

DISCUSSION

Penetrating injuries to the brain are rare entities, their mortality reaches as far as 75% as described by some authors. The incidence of injuries inflicted by fireguns is higher than knives.

The three most common types of low velocity penetrating head injuries are industrial accidents, suicide attempts and results of criminal assault. The entrance sites of foreign bodies into cranium include the relatively vulnerable portion of the cranial bone as is the temporal squama and the orbital roof. Nathoo, et al, reported only four survivors among 17 patients with penetrating stab lesions in the brainstem; the three patients whose injuries had crossed the brainstem died.

There are described in some reports direct vascular injury in 30% of cases and several complications which cause mortality in early stage, as arteriovenous fistulae, vasospasm, haemorrhage and infection, wich depend in the site and how deep the injury was. In our patient the predominant complication was the neurologic deficit characterized by left third cranial nerve lesion and contralateral hemiplegia, due to direct lesion to midbrain affecting the left cerebral peduncle and hence the pyramidal tract and its tegmentum, where the third cranial nerve nuclei are localized.

There are several reports of neurologic déficits secondary to penetrating lesions like parkinsonism described by Rondot et al in 1994. Parinaud syndrome after a penetrating wound in midbrain was described in 2010 by Sumit et al. The most famous case is the penetraing wound suffered by Phineas Gage with prefrontal syndrome described in 1968 by Harlow.

Weber syndrome is described often secondary to primary haemorrhages in midbrain, aneurysmal rupture, and tumours or demyelinating disease; unlike those reports, we describe the first case of weber syndrome secondary to penetrating injury in midbrain by a knife with clinical and radiological improvement.

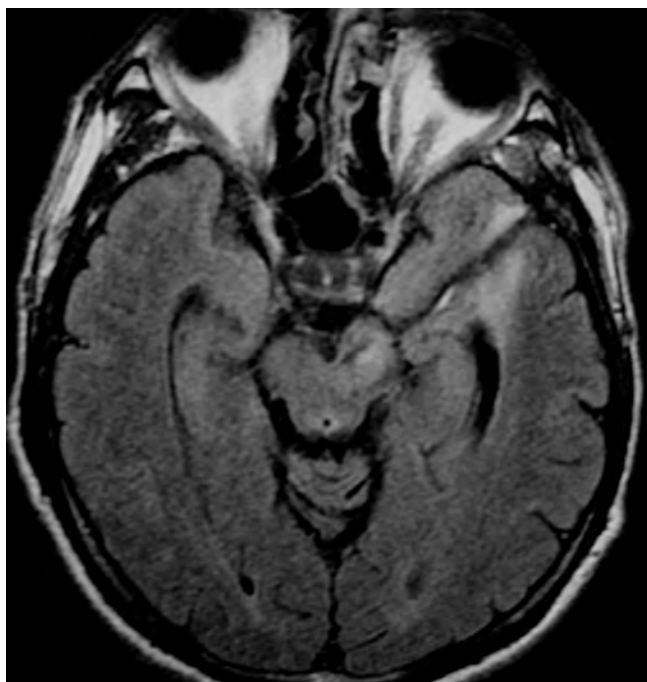


Figure 3. MRI Fluid-Attenuated Inversion Recovery secuencia showing well defined hypointense trajectory from malar region through temporal parenchyma into left cerebral peduncle with edema of the latter.

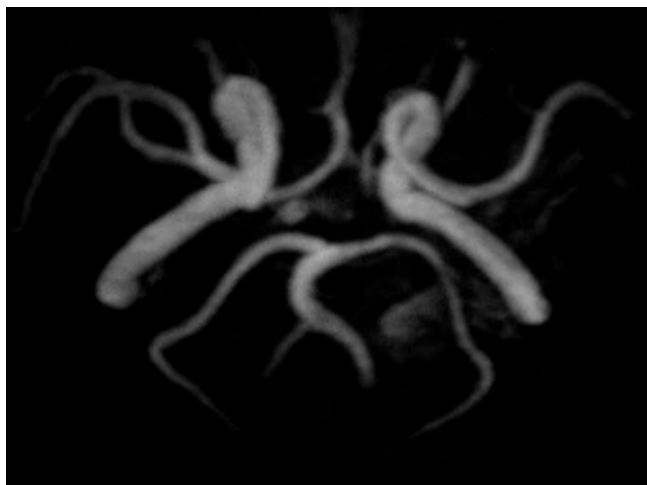


Figure 4. MRI angiographic reconstruction revealed no structural lesion in any cerebral vessel.

CONCLUSION

We conclude that intracranial penetrating wounds are still entities with high morbidity and mortality with important secuelae, all depending in the localization of the injury, most of the times these limit the reintegration of the patient to his normal life.

BIBLIOGRAPHY CONSULTING

- Sumit S, Hitesh GB, Survival after a penetrating injury traversing midbrain-case report. *Br J Neurosurg* 2010;24(4): 477-8.
- Manning CT, Hallam D, Britz WG, Survival with good outcome after traversing brainstem injury. *Neurosurgery* 2008;62:E749.
- Nathoo N, Boodhoo H, Nadvi SS, Naidoo SR, Gouws E. Transcranial brainstem stab injuries: a retrospective analysis of 17 patients. *Neurosurgery* 2000;47:1117-23.
- Paramhans D, Shukla S, Batra A, Mathur KR. Successful removal of an impacted metallic arrowhead penetrating up to the brainstem. *J Emerg Trauma Shock* 2010;3(3):303.
- Ferreira de Andrade A, De Almeida A. Penetrating screwdriver injury to the brainstem *Journal of Neurosurgery* 2006;104:853.
- Lawson-Smith M, Smith S, Leach J, Cadoux-Hudson T. Lateral medullary syndrome caused by preneetrating head injury. *J Clin Neurosci* 2006; 13:792-4.
- Laurel Q, Robert E, William S. Transorbital penetrating brainstem injuries. *Arch Ophthalmol* 2006;124,914-6.
- Kjelland C, Thirsk W, Penetrating craniofacial trauma from a vice clamp: case report and discussion. *CJEM* 2011;13(1):57-61.
- Orbay AS, Uysal OA, Lyigün O. Güldogus FE. Unusual penetrating faciocranial injury caused by a knife: a case report. *J Craniomaxillofacial Surg* 1997;(25):279-81.
- Gökcek C, Erdem Y, Köktek E. Intracranial foreing body. *Turk Neurosurg* 2007;(17):2,121-4.
- Okay O, Dađliođlu E, Ergungor F. Orbitocerebral injury by a knife: case report. *Neurocirugía* 2009;20:467-9.
- Bozzeto AP, Ferraz C, Hildo AL. Penetrating screwdriver wound to the head. *Arq Neuropsiquiatr* 2008;66(1):93-5.
- De Jongh K, Dohmen D, Salgado R. «William Tell» Injury: MDCT of an arrow through the head. *AJR* 2004; 182:1551-3.
- Yaralanmasýna H, Bađlý B, Üçeri*kin B. Sunumu O. Brain injury due to air gun shot: report of three adult cases. *Turkish J Trauma Emergency Surg* 2010;16(5):473-6.
- Zazpe I, Vázquez A, Beaumont C, Bardón A. Heridas múltiples penetrantes intracraneales causadas por pistola de clavos: caso clínico. *Neurocirugía* 2006;17:544-9.
- Colleen K, Warren T. Penetrating craniofacial trauma from a vice clamp:case report and discussion. *CJEM* 2011;13(1):57-61.
- Weber HD. A contribution to the pathology of the crura cerebri. *Med Chir Trans* 1863;46:121-140.1.
- Rondot P, Bathien N, De Recondo J. Dystonia-parkinsonism syndrome resulting from a bullet injury in the midbrain. *J Neurol Neurosurg Psychiatry* 1994;57:658-66.
- García-Molina J. Phineas Gage y el enigma del córtex prefrontal. *Neurol* 2010;68:1-6.
- De la Torre IA, López A, García BC, Parálisis del nervio oculomotor secundaria a hemorragia primaria aguda en el mesencéfalo. *Arch Neurocién* 2007;(12)4:254-7.
- Isikay CT, Yücesan C, Yücemen C, Çulcuoglu C, Mutluer N. Isolated nuclear oculomotor nerve syndrome due to mesencephalic hematoma. *Acta Neurol Belg* 2000;100:248-51.
- Ibarra A, Aguilar R, García C, Silva F. Parálisis del nervio oculomotor secundaria a hemorragia primaria aguda en el mesencéfalo. *Arch Neurocién* 2007;12(4):254-7.
- Umasankar U, Huwez FU. A patient with reversible pupil-sparing Weber syndrome. *Neurol India* 2003;51:388-9.
- Jürgen M, Thömke F. Classical crossed brain stem syndromes: myth or reality? *J Neurol* 2009;256:898-903.